

*Case Report*

## 18F-FDG-PET CT Features of Colo-Colic Intussusceptions in Patient with Colonic Carcinoma

Fathinul Fikri, A. S.<sup>1\*</sup>, Noraini Sarina, A.<sup>1</sup>, Shahrin, S.<sup>2</sup> and Abdul Jalil, N.<sup>1</sup>

*Centre for Diagnostic Nuclear Imaging, Universiti Putra Malaysia, 43400 Serdang, Selangor, Malaysia*

*Department of Diagnostic Imaging, KPJ Rawang Specialist Hospital, Jalan Rawang, Bandar Baru Rawang, 48000 Rawang, Selangor*

### ABSTRACT

Colo-colic intussusception is a rare manifestation of a primary tumour in an adult patient. This article aims to document the rarity of colo-colic intussusception features on the 18 FDG- PET-CT in a patient with primary colonic carcinoma. An 18 FDG-PET-CT was performed for the purpose of pretreatment staging of a colonic carcinoma in a 61-year-old man following a diagnostic colonoscopic biopsy. He presented with abdominal distension and peri-rectal bleeding for a month. The fused 18 F-FDG PET-CT image revealed an FDG-avid mass in the left hemicolon showing a rim of FDG avidity denoting the head of intussusceptum. There are also multiple FDG-avid nodules seen along the anti-mesenteric colonic fat suspicious for lymph nodes metastasis. Debulking of tumour revealed a mucinous adenocarcinoma of colon with a metastatic lymph node. 18 FDG PET-CT features of intussusception in colonic carcinoma have never been described before. It can potentially become a preferred diagnostic tool in delineating a potential tumour mass within the intussusceptions that help improve prognosis in patients with malignancy

*Keywords:* Colonic carcinoma, synchronous tumour, adult intussusception, colo-colic intussusceptions, FDG PET-CT

#### *Article history:*

Received: 13 July 2015

Accepted: 21 August 2015

#### *E-mail addresses:*

[ahmadsaadff@gmail.com](mailto:ahmadsaadff@gmail.com) (Fathinul Fikri, A. S.),

[surihatiku.sn@gmail.com](mailto:surihatiku.sn@gmail.com) (Noraini Sarina, A.),

[dr\\_shahrinrad@yahoo.com](mailto:dr_shahrinrad@yahoo.com) (Shahrin, S.)

[drimaging@yahoo.com](mailto:drimaging@yahoo.com) (Abdul Jalil, N.)

\*Corresponding Author

### INTRODUCTION

Intussusception occurs when one loop of bowel (intussusceptum) telescopes into an adjacent segment (intussusciens). Intussusception is rarely found in adults, with only approximately 5% of all intussusceptions occurring in adults, often associated with a malignant lead point (Young et al., 2006).

More than one half of large-bowel intussusceptions are associated with malignant lesions with the incidence of primary cancers in the colon at about 2 to 5% (Chien-Chih et al., 2013). Affected adults are rarely present with intestinal obstruction (Gayer et al., 2002).

At large diagnostic work of the intussusception is by conventional imaging technique i.e. abdominal radiography, barium enema, upper gastrointestinal series and ultrasound following further evaluation of the suspected intestinal obstruction. Computed Tomography (CT) is a routine examination as it will clearly demonstrate the site of intussusceptions given its compatibility in visualising a gaseous structure. In addition, CT could delineate a complex sausage-shaped mass, the 'target' lesion, consisting of the outer intussusciens and the central intussusceptum (Gayer et al., 2002). There is often an eccentric area of fat density within the mass representing the intussuscepted mesenteric fat, and the mesenteric vessels are often visible within it (Gayer et al., 2002). Furthermore, a rim of oral contrast medium may at times be noted encircling the intussusceptum conforming along the opposing walls of the intussusceptum and the intussusciens.

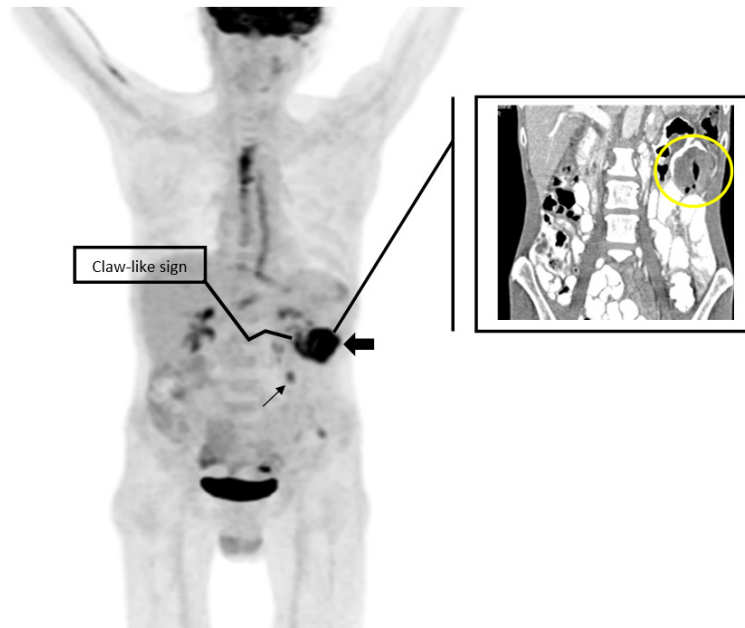
The Positron Emission Tomography-Computed Tomography (PET/CT) utilising Flurodeoxyglucose (FDG) is a sensitive imaging tool in localising mass lesions. Aside from its role in preoperative evaluation of tumours, the PET-CT feature of intussusceptions has never been reported to our best knowledge. We document a PET-CT feature of a rare case of the colo-colonic intussusception secondary to colonic cancer.

## CASE REPORT

A 61-year-old man presented with an altered bowel habit for months associated with constitutional symptoms and tenesmus. On physical examination, there appeared to be a vague mass in the left lumbar region. Diagnostic colonoscopy revealed a friable obstructing tumour of approximately 70-cm distance from the anal verge. An FDG PET-CT of the whole body revealed an FDG-intense mass at the descending colon proximally measuring about 6 cm x 4 cm x 5.7 cm in diameter with a claw-like FDF-avidity at the proximal descending colon for which the correlated CT revealed a bowel-telescoping, denoting the site of intussusception (Figure 1). There was also a focus of FDG avidity at the peri-colonic area suspected of hosting a metastatic lymph node.

The patient underwent a left hemicolectomy and omentectomy. Intraoperative findings showed an obstructive colon tumour with intussusception at the splenic flexure with dilated proximal colon. There were also multiple lymph nodes seen along the mesentery and omentum with minimal ascites without peritoneal involvement. An intussusception at the tumour growth of the splenic flexure was confirmed.

Histologically, the tumour was a moderately differentiated mucinous adenocarcinoma which had invaded the muscular layer with only one adjacent pathological lymph node metastasis (T3N1M0) modified Dukes C1. Surgical resection with adjuvant chemotherapy was planned for the patient.



*Figure 1.* Maximum intensity projection (MIP) image of the FDG PET-CT showing an FDG-avid mass (SUVmax: 8.9) (arrow head) with a claw-like FDF-avidity (wall of the opposing inflammatory walls of the intussusceptum and the intussusciptions) at the proximal descending colon (blue arrow). The correlated CT image revealed the site of intusseption (telescoping of the bowel lumen). There is also a focal FDG uptake lesion (long arrow) suggestive of lymph node metastasis.

## DISCUSSION

In nearly two thirds of adult patients with colo-colonic tumours, intussusception is strongly associated with a malignant lead point (Gayer et al., 2002). Typically, adults presented with chronic complaints such as intermittent crampy abdominal pain, nausea or bloody stools. In this case, the patient presented with altered bowel habits associated with constitutional symptoms. The erect plain radiograph is not specific to characterise the intussusception aside from revealing evidence of air-fluid levels and the dilated colonic segment proximal to the intussusception. A recent Best Evidence Topic report found that the sensitivity of plain radiology ranges from 36 to 90% and a specificity of 45-90% (Broomfield., 2008). Routinely, single contrast barium enema is more popular in neonatal intussusception. Air, water-soluble or barium contrast enemas are diagnostic approaches with significant therapeutic values, with reduction rates between 70% and 90%, which characterises the intussusception as a coiled-spring contrast fill. (Daneman et al., 2005). The patient underwent 18F-FDG PET-CT for pre-operative staging following a detection of mass lesion in the descending colon on the colonoscopy, which revealed an FDG-avid mass in the descending colon with suspicion of mesenteric lymph node metastasis. Peculiarly in our case, the nature of the leading cause for an intussusception was poorly defined on the corroborated CT images. The sensitivity of CT scans to correctly diagnose intussusception has been reported from 71.4%-87.5% while its specificity in adults has been reported to be 100% as verified by the subsequent surgery (Erkan et al., 2005). Therefore, a long intestinal

tube visualised in the centre of the colon may not be readily distinguished as an interposition of a malignant mass (Gayer et al., 2002).

With the use of FDG PET-CT scanning in this case, the increased FDG activity of the lead mass confirmed the site of the primary tumour origin. The increased FDG avidity could also be attributable to infection of the intussusception, for which inflammatory cells constitute a major portion of increased FDG accumulation in tumour tissue (Chamroonrat et al., 2010). The claw-like FDG avidity seen at the intussusceptum is likely the hallmark of the opposing inflammatory walls of the intussusceptum and the intussusciptens. These case documented that 18-FDG-PET-CT can be utilised as a tool for detection of intussusception given its superiority in delineating an infective focus and the detection of primary colonic carcinoma (Fathinul et al., 2013).

## CONCLUSION

18-FDG-PET-CT features of intussusception in colonic carcinoma have never been described before. It can potentially become a preferred diagnostic tool in delineating a potential tumour mass within the intussusceptions, which will help improve prognosis in patients with malignancy.

## REFERENCES

- Broomfield, D. (2008). Best evidence topic report. Role of plain abdominal radiograph in the diagnosis of intussusception. *Emergency Medicine Journal*, 25,106-107.
- Chien-Chih Y., Sheng-Chuan H., Chih-Pin C., & Yung-Hsi K. (2013). Synchronous triple carcinoma of the colon and rectum. *World Journal of Surgical Oncology*, 11, 66.
- Daneman A., & Navarro O. (2004). Intussusception. Part 2: An update on the evolution of management. *Pediatric Radiology*, 34(2), 97-108.
- Gayer G., R. Zissin, A. S., Papa M., & Hertz M. (2002). Adult intussusception a CT diagnosis. *British Journal of Radiology*, 75(890), 185-190.
- Chamroonrat, W., Cheng, G., Servaes, S., & Zhuang, H. (2010). Intussusception incidentally detected by FDG-PET/CT in a pediatric lymphoma patient. *Annal of Nuclear Medicine*, 24(7), 555-558.
- Erkan, N., Hacıyanlı, M., Yildirim, M., Sayhan, H., Vardar, E., & Polat, A. F. (2005). Intussusception in adults: An unusual and challenging condition for surgeons. *Internal Journal Colorectal Disease* 20(5), 452-456.
- Fathinul, F., Nordin, A. J., & Lau, F. W. (2013). 18[F] FDG-PET/CT is a useful molecular marker in evaluating tumour aggressiveness; A revised understanding of an in-vivo FDG PET imaging that alludes the alteration of cancer biology. *Cell Biochemistry and Biophysic*, 66(1), 37-43.
- Young, H. K, Michael, A. B., & Mukesh, G. H. (2006). Adult intestinal intussusception: CT appearances and identification of a causative lead point. *Radiographics*, 26(3), 733-44.